



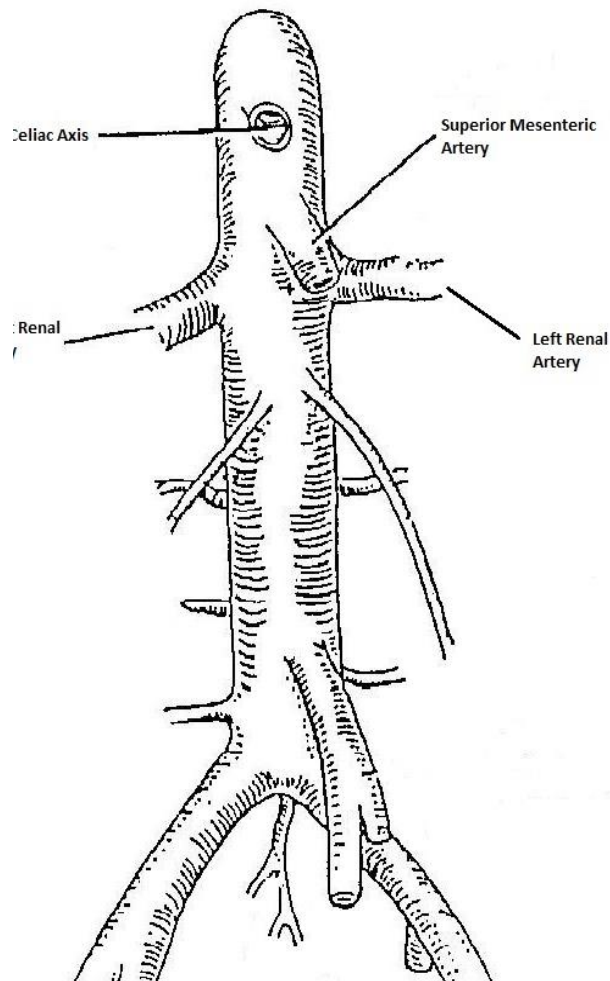
CARDIORISK AAA SCREENING

Patient Name: Young, Joe Date: 8/4/2021

DOB: 7/11/1951 Sex: M

Referring Provider: Zachary Young, DO

Vascular Technician: Dana Johannesson



Aorta Prox

1.7 cm Trans X 1.5 cm AP

Aorta Mid

1.5 cm Trans X 1.4 cm AP

Aorta Distal

1.2 cm Trans X 1.2 cm AP

Comments: No Abdominal Aortic Aneurysm was identified in the submitted images. There was a small amount of calcified plaque identified in the Abdominal Aorta.



